

# A Simplified Approach to Midface Aging

Ryan N. Heffelfinger, MD; Keith E. Blackwell, MD; Jeffrey Rawnsley, MD; Gregory S. Keller, MD

**W**e review herein our experience with subperiosteal midface-lifting under direct vision with a simple fixation technique. The technical aspects of the procedure are described in detail. A total of 121 patients underwent midface-lifting and meloplication with the 82/18 L-lactide/glycolide device (Coapt Endotine Midface ST 4.5; Coapt Technologies, Palo Alto, Calif) by both the senior (G.S.K.) and junior (R.N.H.) authors. The senior author's experience included 110 patients over a 26-month period. Thirty-two of these cases were isolated procedures. The other 78 were performed in conjunction with various procedures, most commonly rhytidectomy. There were no revisions during this period. Two cases of "puckering" were noted. Both were immediately corrected, one with fat injection and one with poly-L-lactic acid injection (Sculptra; Dermik Aesthetics, distributed by Besse Medical Supply, West Chester, Ohio). The junior author's experience included 11 cases over an 8-month period. Two cases of asymmetry were noted. One was corrected with fat injection, and the other required revision. Subperiosteal midface-lifting and meloplication using the Coapt Endotine Midface ST 4.5 device is a simple, effective technique that can be quickly learned and applied.

*Arch Facial Plast Surg.* 2007;9:48-55

Fullness of the cheek represents youthfulness. In the process of aging, a constant hollowness of the midface develops. As a result, a patient may display an appearance that is tired, old, or sad.

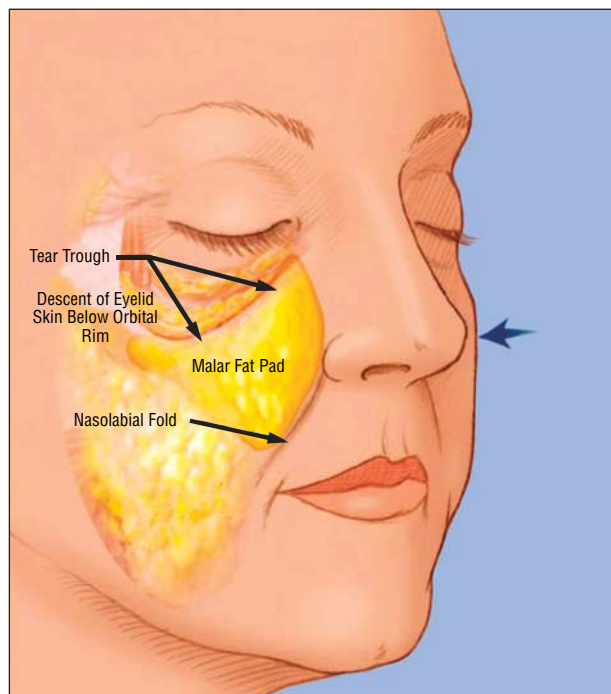
Weakening of the malar and orbital ligaments is a major component of the aging process. The result is a downward and medial displacement of the malar fat pad or panniculus adiposus over the fixed ligaments of the nasolabial fold. A gap or crease, angled posteroinferiorly, forms between the malar eminence and the fallen fat pad. This is referred to as the "cheek hollow." The fat over the malar emi-

nence is left standing, accentuating the malar bag (**Figure 1**).

Another anatomical change that occurs is the weakening of the orbital ligaments, which contributes to hollowness under the orbit. This is referred to as the "orbital hollow." The malar fat pad, which in youth was at the level of the orbital rim, falls downward and medially, producing this hollowness. This concavity, which is below the convexity of the ocular globe and orbital fat, accentuates and no longer covers the bulge of herniated orbital fat. This produces the "double contour" deformity characteristic of the aging orbital/midface complex.

A volume loss of the midface also contributes to the aging process. Thus, many

**Author Affiliations:** Division of Head and Neck Surgery, UCLA Medical Center, University of California, Los Angeles.



**Figure 1.** Illustration demonstrates the process of midface aging. As the malar fat pad descends, the nasolabial fold is accentuated. The orbital rim is left covered only by thin eyelid skin, and the tear-trough deformity becomes apparent.

physicians use fat injections or malar/submalar implants in an attempt to correct this aspect of aging. These have their own set of problems and complications.<sup>1,2</sup>

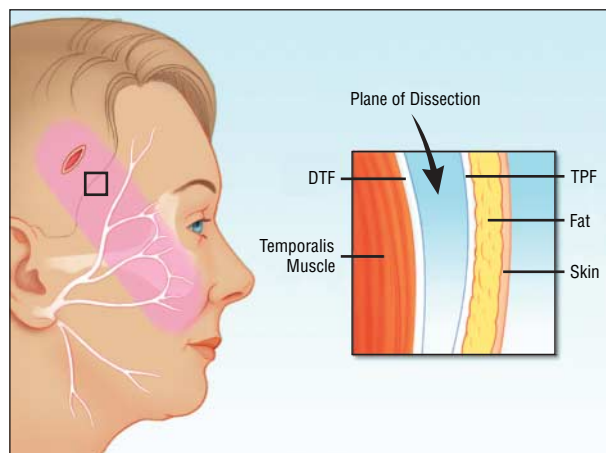
Finally, the zygomaticus major and minor muscles suspend the ligamentous and muscular connections of the midface. These connections weaken and fall, producing an “oral frown.” The collapse of the muscular structures, with their associated ligaments and fat pad, results in a droop of the corner of the mouth and deepens the labiomental fold.

The senior author (G.S.K.) has lifted and augmented the midface using different techniques over the last quarter century.<sup>3-6</sup> These techniques, while all useful, required either wide dissections (open or endoscopic) or treated only a portion of the aging problems of the midface. Suture suspension techniques have proven minimally invasive and are associated with low morbidity, but we continue to search for a solution that more completely addresses all of the problems of midface aging (eg, volume augmentation, fat pad and ligament suspension, and muscle elevation).<sup>7</sup>

Recently, a new fixation technology with a spiked suspension and fixation device (Endotine ST 4.5, Coapt Technologies, Palo Alto, Calif) has allowed us to develop a single incision technique that requires only 10 to 15 minutes per side after surgeon familiarization. While the recovery period is compatible with string or loop procedures, this technique more completely addresses the midface aging process.

#### TECHNIQUE

Subperiosteal meloplication is performed under direct observation. An incision is planned 2 cm behind the tem-



**Figure 2.** Illustration shows the location of incision and plane of dissection. This plane is between the deep temporal fascia (DTF) and the temporoparietal fascia (TPF).

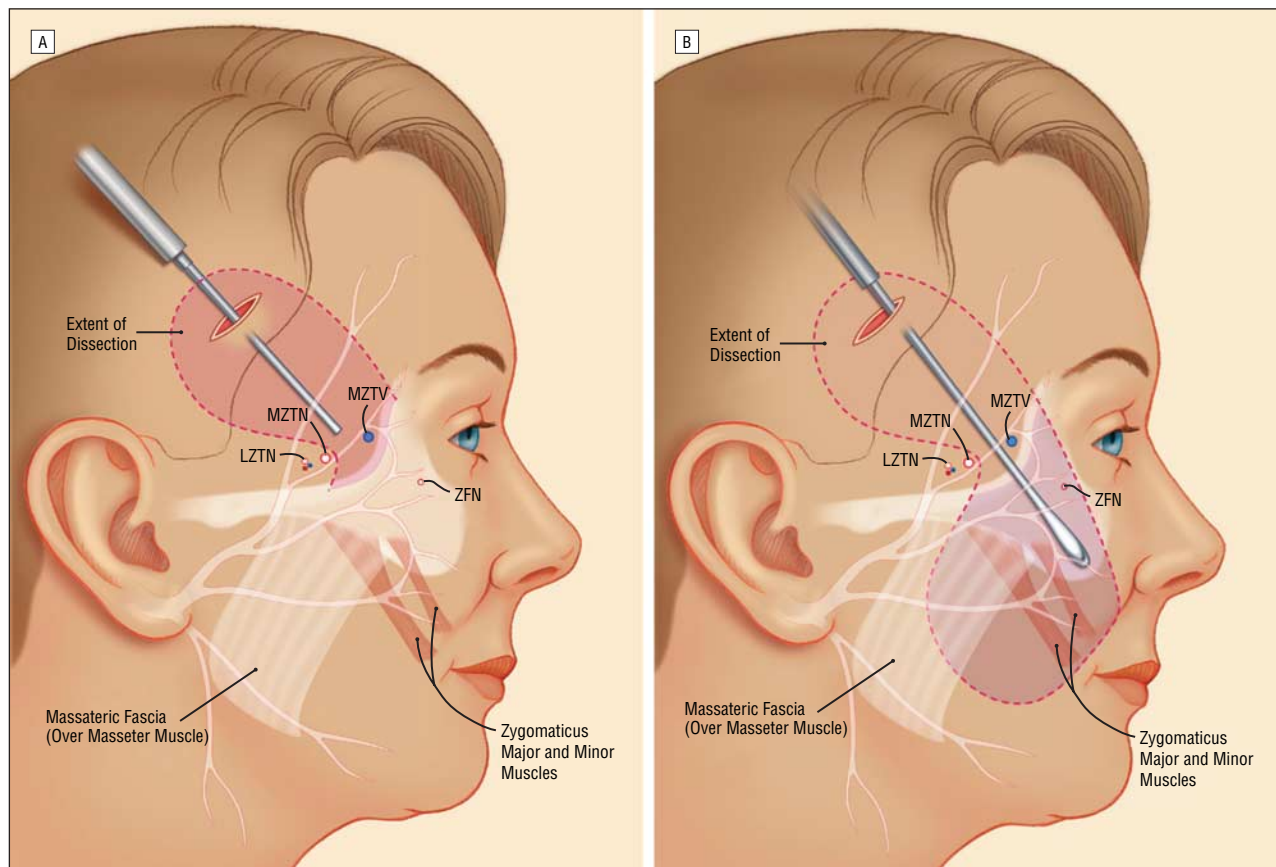
poral hairline perpendicular to an imaginary line drawn from the nasolabial junction to the lateral canthus and carried into the hairline. This imaginary line bisects the incision at its midpoint. In an attempt to camouflage the scar, we originally made this incision as small as possible. We soon realized that a larger incision is equally well hidden behind the hairline and significantly improves exposure. The length of the incision we currently use is approximately 4 cm. This incision is carried down to the superficial layer of deep temporal fascia (**Figure 2**).

Using a gently curved elevator, the physician carries the dissection medially and inferiorly, taking care to stay directly on the superficial layer of deep temporal fascia. A lighted Aufricht retractor or a headlight and a standard Aufricht retractor are used to illuminate the dissection field. The sentinel vein is identified and cauterized. Lateral widening of this dissection above the zygomatic arch is carried out to the second branch of the zygomaticotemporal nerve and vein, which are left intact (**Figure 3A**).

A periosteal elevator is then placed on the malar eminence. Using tactile sensation under direct observation, the physician elevates the periosteum of the malar eminence and the medial one third of the zygomatic arch. It is important to use careful, short sweeping motions of the elevator. A protective finger of the left hand (if the physician is right handed) palpates and guards the foramen of the infraorbital nerve. Elevation near the infraorbital neurovascular bundle is performed with upward “prying” motions of the periosteum that do not endanger the nerve.

Dissection is then carried downward via palpation and direct observation over the masseteric fascia, with gently sweeping downward motions. The dissection can proceed as far medially as necessary, usually elevating the nasolabial fold. The arcus marginalis is freed insofar as possible, while avoiding the infraorbital nerve (**Figure 3B**).

The Aufricht elevator is then used to visualize the dissection. Usually, at this point, the precanthal ligament is released with scissors dissection in the supraperi-



**Figure 3.** Illustration depicts the upper (A) and lower (B) dissection. The subperiosteal plane is entered over the malar eminence, remaining medial to and preserving the medial zygomaticotemporal nerve (MZTN). The medial zygomaticotemporal vein (MZTV) is often encountered and is cauterized at its deep aspect and transected. LZTN indicates lateral zygomaticotemporal nerve; ZFN, zygomaticofacial nerve.

osteal plane. This maneuver widens the dissection cavity to accommodate the spiked device.

The device is encased in a protective plastic sheath. The entire complex is placed into the dissection cavity. The spiked portion of the device is positioned immediately lateral to the nasolabial fold. The sheath trigger is then squeezed, the spikes are engaged into periosteum with the aid of digital pressure, and the sheath is removed.

The device, with the sheath removed, has a “leash” that extends from the device upwards and backward into the temporal incision. This leash is pulled posterosuperiorly until the spiked portion is in approximate vertical alignment with the midpupillary line. If it appears that too much or too little elevation has occurred, the device is disengaged by pinching and lifting the cheek fat. Repositioning can proceed as necessary. Generally, as the device is relocated in a more lateral direction, the less elevation will be seen. Conversely, the more medial the original position of the spikes, greater vertical movement is possible.

If necessary, a gingivobuccal incision is made to improve exposure of the midface and ensure the proper plane of dissection. It is also useful if the device is disengaged initially in an improper position, since it is difficult to reposition the spiked apparatus from the temporal incision alone. We used gingivobuccal incisions in all of our initial cases. With more experience, we found that we

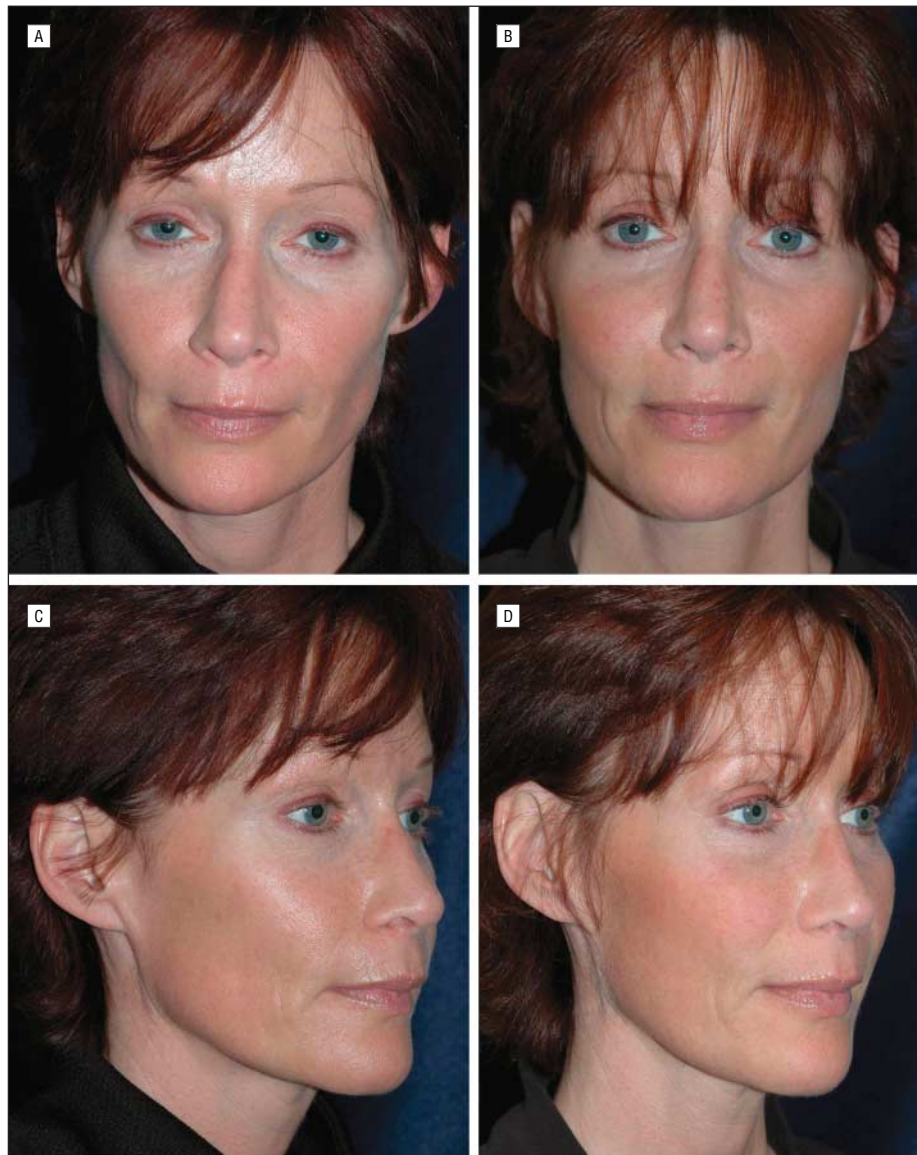could perform adequate dissection and place the device properly through the temporal incision alone.

With posterosuperior tension on the leash, a large absorbable suture is placed to fix the device to the superficial layer of deep temporal fascia. The cut margin of temporoparietal fascia is grasped, pulled superiorly, and sutured to the superficial layer of deep temporal fascia. The incision is closed with staples. Application of a pressure dressing is optional. Patients are given antibiotics for 7 to 10 days following the procedure; oral flora coverage is crucial if a gingivobuccal sulcus incision was used. A soft diet is followed for 2 days postoperatively.

## RESULTS

From December 2003 to February 2006, the senior author performed 110 of the described procedures: 32 were independent procedures, and 78 were performed with ancillary procedures. The most common ancillary procedure was rhytidectomy (59 patients), followed by blepharoplasty (28 patients) and endoscopic browlift (17 patients). There were 2 cases of “puckering” overlying the spiked portion of the device. One patient was treated with autologous fat injection (approximately 3 mL), the other with serial injections of poly-L-lactic acid (Sculptra; Dermik Aesthetics, dis-





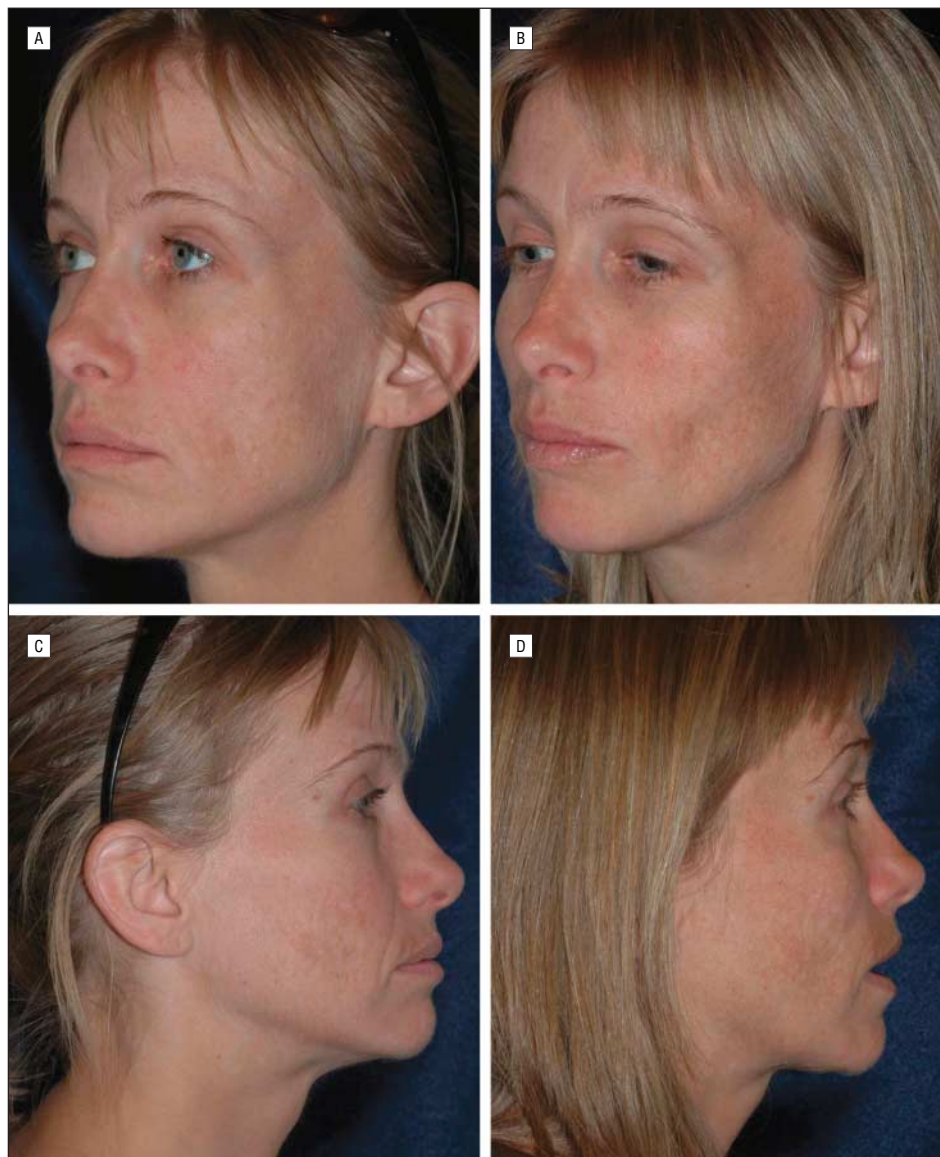**Figure 4.** Preoperative (A and C) and 10-month postoperative (B and D) photographs of a female patient who underwent subperiosteal midface-lift and laser skin tightening of the lower face and neck (3 treatment sessions).

tributed by Besse Medical Supply, West Chester, Ohio). No patients required revision or implant removal and/or replacement. Complaints of lip hypesthesia, suture irritation, and pain related to the gingivobuccal incision were frequent early in the development of our technique. As we evolved to omit this incision, this short-term complication was eliminated. In the group that had gingivobuccal incisions, these problems were transient and resolved during the period of observation.

From July 2005 to February 2006, the junior author (R.N.H.) performed the procedure on 10 patients. It was performed as an isolated procedure in 1 patient and in conjunction with rhytidectomy in the other 9 patients. The second patient in this series developed an asymmetry that was corrected with autologous fat injection. The third patient had an asymmetry that was due to either improper placement or incomplete engagement of the spikes with the periosteum and/or malar mound. This required revision

and repositioning of the implant. This was performed with the patient under local anesthesia using both the temporal and gingivobuccal incisions. Through the temporal incision, the leash was released from the deep temporalis fascia and freed from the surrounding tissue. Intraorally, the malar mound was elevated from the spikes and repositioned under direct vision. The leash was sutured to the superficial layer of the deep temporal fascia, and the wounds were closed as usual. Ten days postoperatively, this patient developed a cellulitis, which responded to treatment with oral antibiotics. The most common postoperative complaint was transient lip numbness (4 patients). The last 3 patients in the junior author's series did not require gingivobuccal incisions, thus eliminating this complication.

The longest follow up is 26 months, which involved a male patient with the device inserted as an independent procedure. The range of follow-up is 1 to 26 months. Representative patients are seen in **Figures 4, 5, 6, 7, and 8**. Results are stable over the follow-up period.



**Figure 5.** Preoperative (A and C) and postoperative (B and D) photographs of a female patient who underwent a midface-lift as an isolated procedure (4-month follow-up period).

#### COMMENT

As the mechanisms of midface aging have been elucidated, techniques and devices that make elevation of the midface easier to perform were developed.<sup>3-9</sup> Specifically, we believe that no single solution addresses volume augmentation, fat pad and ligament suspension, and muscle elevation in a simple procedure. Our technique of subperiosteal midface-lifting and suspension using the Coapt Endotine ST 4.5 device is a potential step toward this direction.

Our observations indicate that the following occur after the procedure:

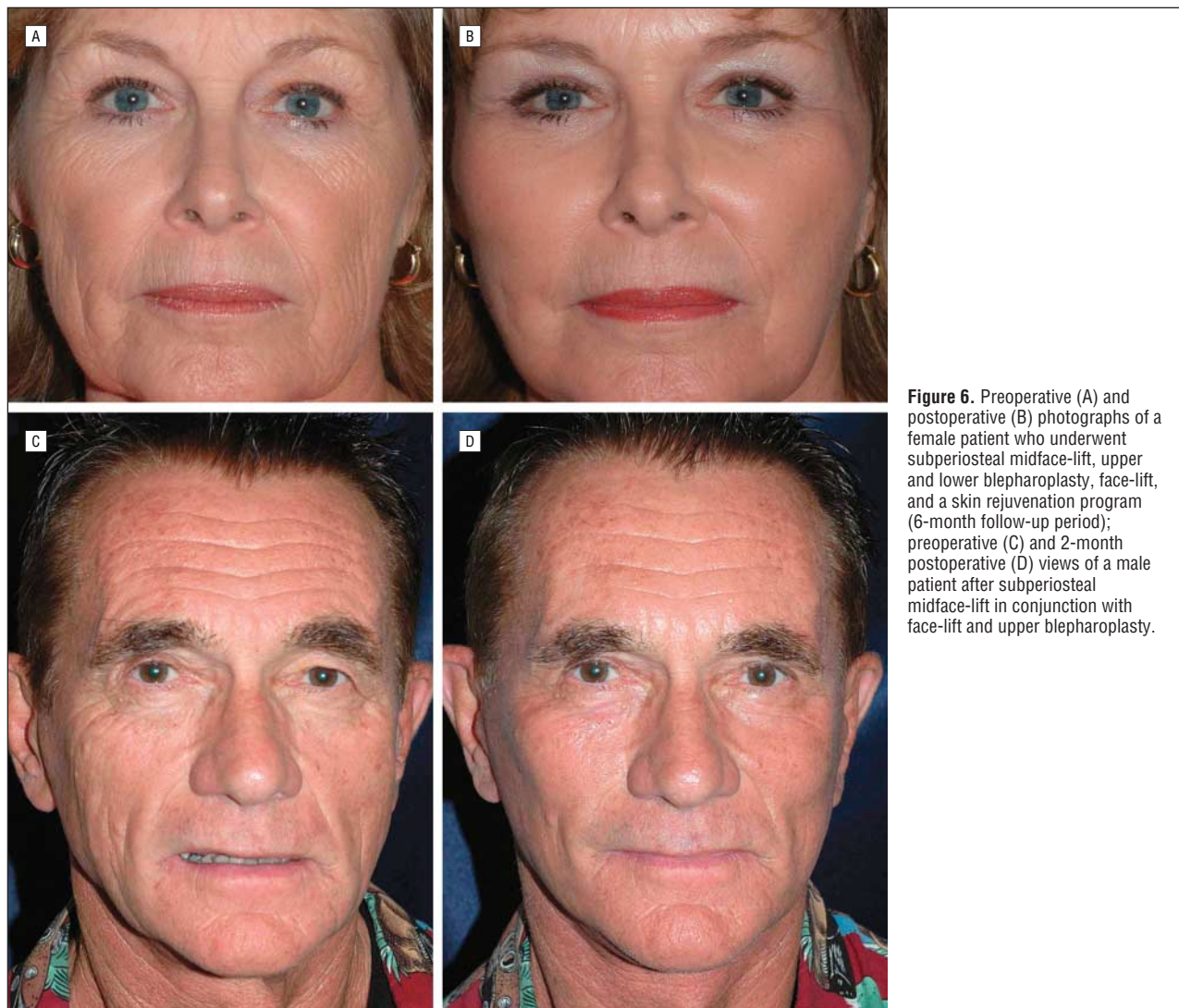
1. The cheek mound advances upward and backward. A tremendous amount of vertical lift is produced. The fat pad is repositioned, diminishing the orbital hollow and the "double contour deformity."
2. A volume augmentation is enhanced by meloplication that fills in both the "orbital hollow" and the "cheek hollow."

3. The nasolabial fold is diminished.
4. The "oral frown" is diminished, to a degree.
5. Malar bags are diminished, to a degree.

Standard superficial musculoaponeurotic system rhytidectomy techniques are inadequate at correcting midface aging.<sup>10</sup> Deep-plane lifting addresses the midface to a greater degree, although the technique is challenging, and the long-term rewards in the midface are modest.<sup>11</sup> In an attempt to specifically address the midface, techniques have been reported that similarly require advanced training and technical expertise.<sup>5,6</sup> We (and others) have reported experience with a simple technique, the percutaneous suspension lift.<sup>7-9,12</sup> While this remains a good technique in selected patients, the issue of foreign body reaction and longevity of elevation remain. In addition, it does not address all of the components of midface aging.

The long-term results of the senior author show this to be a reproducible technique with little risk of complications. As with any procedure, there is a learn-





**Figure 6.** Preoperative (A) and postoperative (B) photographs of a female patient who underwent subperiosteal midface-lift, upper and lower blepharoplasty, face-lift, and a skin rejuvenation program (6-month follow-up period); preoperative (C) and 2-month postoperative (D) views of a male patient after subperiosteal midface-lift in conjunction with face-lift and upper blepharoplasty.

ing curve to overcome when first performing this technique. This is demonstrated by the junior author's experience.

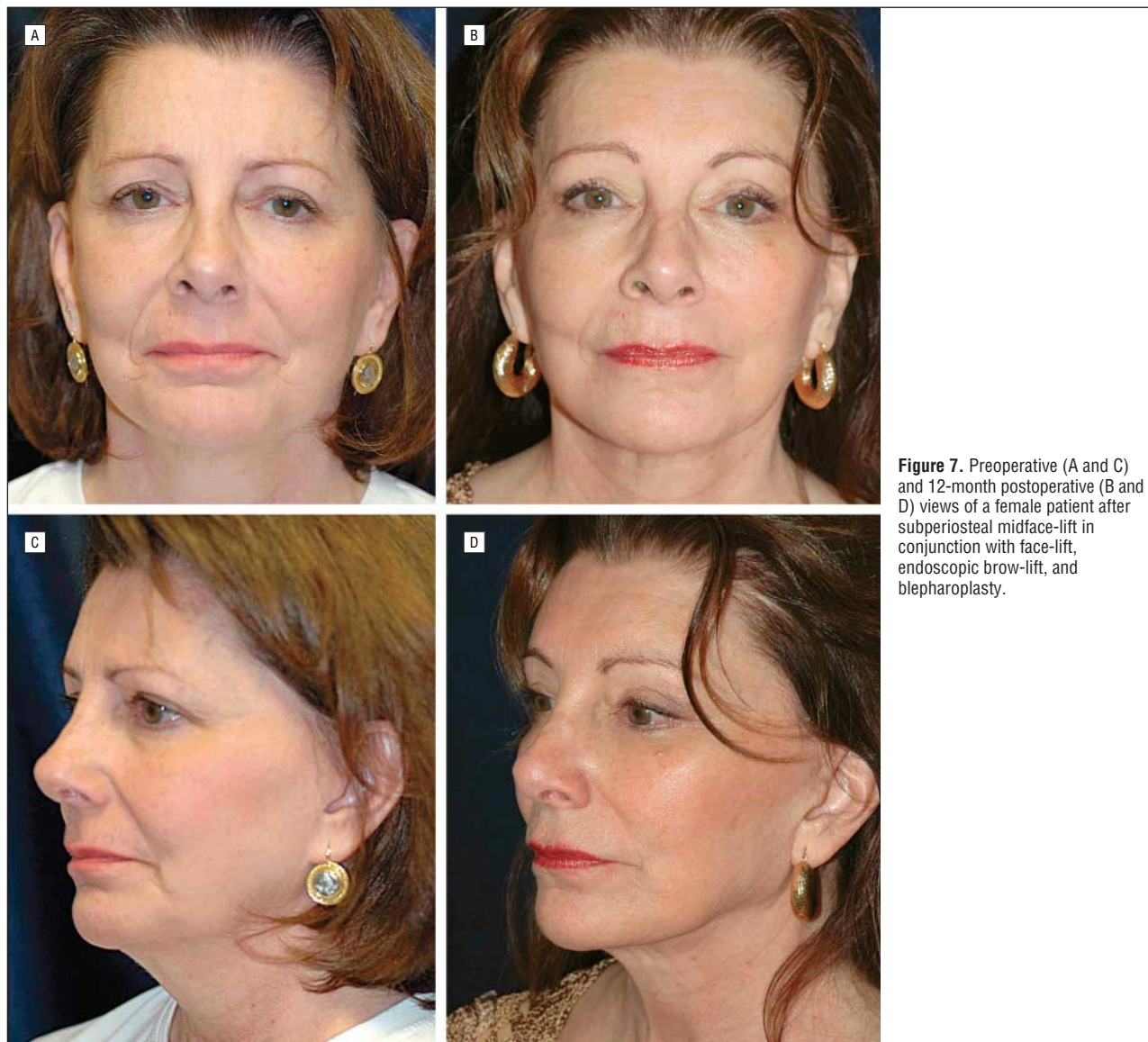Specifics of the Coapt device can be found on their Web site (<http://www.coaptsystems.com>). The device is bioabsorbable, with a reported reduction in strength and mass of 95% and 50%, respectively, in 5 months time. In our experience, the device is rarely palpable after 8 to 10 months. As an isolated procedure, we found that patients may experience edema and ecchymosis that usually resolves enough for public appearance after approximately 5 days. The addition of a gingivobuccal incision seems to add 2 to 3 days to this recovery period.

Several groups of patients can benefit from this procedure. Younger patients with isolated midface aging are frequently unwilling to undergo face-lift surgery. These patients often present with isolated aging of the midface. Patients in the middle to older age group can benefit from this procedure in conjunction with a face-lift or other procedures that are invasive, noninvasive, or minimally invasive. In addition, midface elevation is

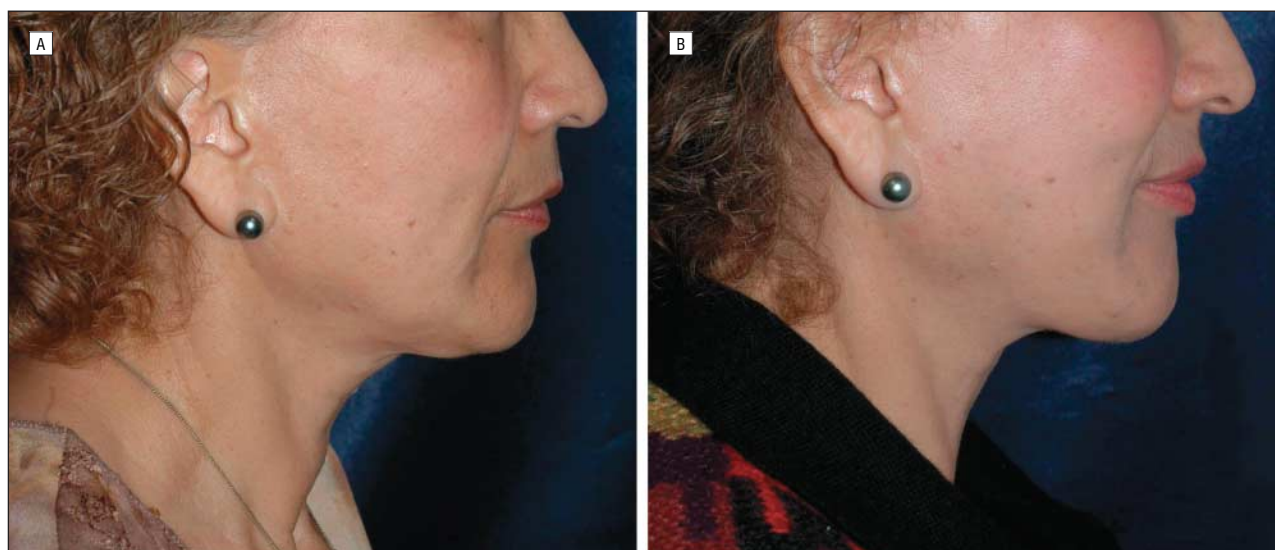often useful as a face-lift "touch up" in the properly selected patient.

All age groups can benefit from ancillary procedures that are performed in conjunction with midface elevation. Fat and/or poly-L-lactic acid injections, radiofrequency, or laser skin-tightening procedures (THERMAGE, Hayward, Calif; Syneron, Yokneam, Israel; and Alma, Caesarea, Israel), fillers (Radiesse; Bioform Medical, San Mateo, Calif; and RESTYLANE; Medicis Aesthetics, Scottsdale, Ariz), and laser resurfacing are all examples of these ancillary procedures. In addition, blepharoplasty and brow-lift are 2 surgical procedures that produce a nice result in conjunction with midface-lifting.

In conclusion, we believe that subperiosteal midface-lifting under direct vision and meloplication of the malar fat pad with the 82/18 L-lactide/glycolide device is a safe, effective procedure with a short learning period. It can be considered a minimally invasive procedure with powerful results. We have inserted these devices under local and general anesthesia. Patients have been uniformly happy and the results stable over the follow-up period.



**Figure 7.** Preoperative (A and C) and 12-month postoperative (B and D) views of a female patient after subperiosteal midface-lift in conjunction with face-lift, endoscopic brow-lift, and blepharoplasty.



**Figure 8.** Preoperative (A) and 9-month postoperative (B) photographs of a female patient after subperiosteal midface-lift in conjunction with an endoscopic brow-lift and face-lift.



Accepted for Publication: September 9, 2006.

**Correspondence:** Gregory S. Keller, MD, 221 West Pueblo St, Suite A, Santa Barbara, CA 93105 (facftr@aol.com).

**Author Contributions:** *Study concept and design:* Rawnsley and Keller. *Acquisition of data:* Heffelfinger and Keller. *Analysis and interpretation of data:* Heffelfinger and Keller. *Drafting of the manuscript:* Heffelfinger and Keller. *Critical revision of the manuscript for important intellectual content:* Heffelfinger, Blackwell, Rawnsley, and Keller. *Statistical analysis:* Heffelfinger. *Administrative, technical, and material support:* Heffelfinger, Blackwell, Rawnsley, and Keller. *Study supervision:* Blackwell, Rawnsley, and Keller.

**Financial Disclosure:** Dr Keller serves on the Medical Board of Coapt Technologies, Palo Alto, Calif.

## REFERENCES

1. Wilkinson TS. Complications in aesthetic malar augmentation. *Plast Reconstr Surg.* 1983;71:643-649.
2. Toledo LS, Mauad R. Fat Injection: a 20-year revision. *Clin Plast Surg.* 2006;33:47-53.
3. Freeman MS. Endoscopic malar pad lift and subperiosteal midface lift. In: Keller GS, ed. *Endoscopic Facial Plastic Surgery.* St Louis, Mo: Mosby-Year Book Inc; 1997:109-136.
4. Owsley JQ. Lifting the malar fat pad for correction of prominent nasolabial folds. *Plast Reconstr Surg.* 1993;91:463-474.
5. Anderson RD, Lo MW. Endoscopic malar/midface suspension procedure. *Plast Reconstr Surg.* 1998;102:2196-2208.
6. Namazie A, Alum D, Keller GS. Current techniques in midface lifting. *Facial Plast Surg Clin North Am.* 2002;10:53-62.
7. Keller GS, Namazie A, Blackwell K, Rawnsley J, Khan S. Elevation of the malar fat pad with a percutaneous technique. *Arch Facial Plast Surg.* 2002;4:20-25.
8. Su NN. Closed suspension mini-cheek lift to reduce the nasolabial fold: a preliminary report. *Am J Cosmetic Surg.* 1995;12:31-34.
9. Sasaki GH, Cohen AT. Meloplication of the malar fat pads by percutaneous cable-suture technique for midface rejuvenation: outcome study (392 cases, 6 years' experience). *Plast Reconstr Surg.* 2002;110:635-654.
10. Stuzin JM, Baker TJ, Gordon HL, Baker TM. Extended SMAS dissection as an approach to midface rejuvenation. *Clin Plast Surg.* 1995;22:295-311.
11. Hamra ST. A study of the long-term effect of malar fat repositioning in face lift surgery: short-term success but long-term failure. *Plast Reconstr Surg.* 2002;110:940-951.
12. Laferriere KA, Castellano RD. Experience with percutaneous suspension of the malar fat pad for midface rejuvenation. *Facial Plast Surg Clin North Am.* 2005;13:393-399.